

SPONTANEOUS HETEROTOPIC PREGNANCY WITH QUADRUPLETS: A RARE CASE

Authors: Dr, Shivani, Dr Kiyoshi Dhankhar ,

Department of Obstetrics and Gynaecology, BPS GMCH(W), Khanpur Kalan, Sonapat, Haryana

Introduction

Spontaneous heterotopic pregnancies with more than two fetuses in natural conception are very rare. Quadruplet pregnancy has an incidence of 1 in 512000 to 1 in 677, 000 births. Abdominal pregnancy is a rare, life-threatening condition in which an embryo is primarily implanted in the fallopian tube, extruded, or expelled, and then secondarily implanted on another intra-abdominal surface with an incidence of 1 in 10,000 live births. So a Quadruplet pregnancy with one fetus in the abdomen is a challenge for an obstetrician.

Clinical Case

We report a case of 24 year old woman, G2P1L1 with 8 months of pregnancy with previous cesarean section (2.5 years ago). She was referred from Panipat i/v/o quadruplet heterotopic pregnancy with suspicion of rupture uterus and delivery of 1st dead fetus at home.

On Examination :

PR – 110/min BP – 102/64 mmHg

Pallor +++

P/A – Vertical scar +

Fetal Parts felt per abdomen , FHS NL by steth

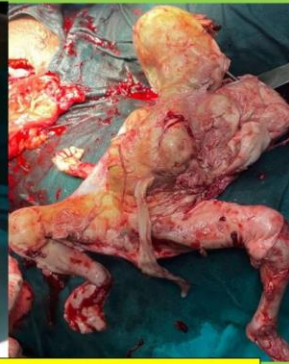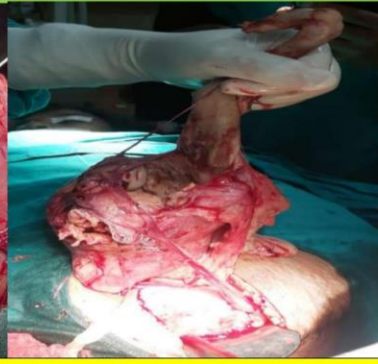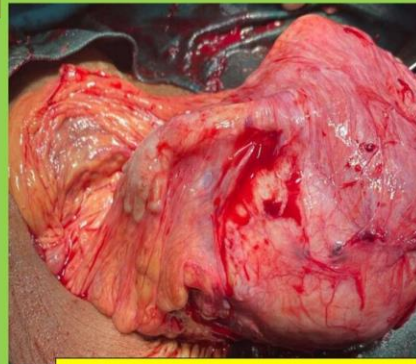
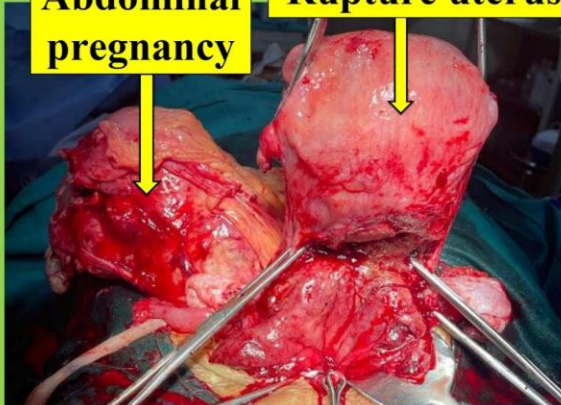
P/V – multiple fetal parts felt

Operative Findings & Post operative period

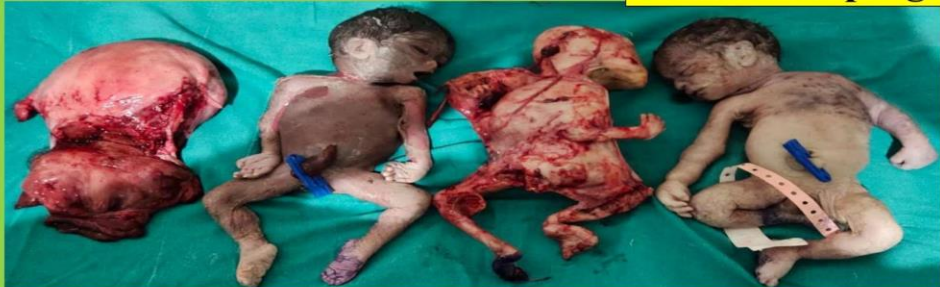- After informed consent, the decision of an emergency laparotomy was taken and performed.
- Vertical incision was given . 2 Dead fetuses (both girls) were extracted weighing 1200 gms and 1935 gms. The 3rd dead fetus (sex not determined) weighing 720 gms was wrapped in a sac within the omentum. The cord was thin and both hands were deformed & contractures were present(secondary abdominal pregnancy).
- Uterus was ruptured, extending up to the cervix and vagina with friable borders, Obstetrics hysterectomy with B/L salpingectomy was done.
- Preoperatively, 1 unit PRBC was transfused. Intraoperatively, 2 units PRBC, 4 units platelet, 4 units FFP were transfused.
- Postoperatively, Patient was taken to SICU where 1 unit PRBC was transfused and she was extubated the next day.
- Her postoperative period was uneventful and was discharged on day 10.

Abdominal pregnancy

Rupture uterus



Abdominal pregnancy with fetus wrapped in omentum



Conclusion

Heterotopic pregnancies with more than two fetuses in natural conception is a grave obstetric condition that needs early diagnosis and prompt management. USG is the diagnostic method of choice. Antenatal care must be strengthened at root level.

Discussion

- This is a rare case of quadruplets in spontaneous heterotopic pregnancy with advanced secondary abdominal pregnancy posing a high risk due to an increase in maternal, fetal and neonatal morbidity and mortality.
- Heterotopic pregnancies in natural conception is estimated to be less frequent than one in 30,000 spontaneous pregnancies.
- Assisted reproductive procedures like IVF are highly contributing to the occurrence of heterotopic pregnancy.
- It is important to be aware that simultaneous intrauterine and extrauterine pregnancy can occur without symptoms and progress to term.

References

- Utalo, T., Getu, J. A unique case of coexisting intrauterine and abdominal pregnancy which progress to term with a positive birth outcome. *BMC Pregnancy Childbirth* 22, 243 (2022). <https://doi.org/10.1186/s12884-022-04561-x>
- Ludwig M, Kaisi M, Bauer O, Diedrich K. The forgotten child: a case of heterotopic, intra-abdominal and intrauterine pregnancy carried to term. *Hum Reprod.* 1999;14:1372–4.